



Original Article

Distraction Osteogenesis Maxillary Expansion (DOME) for adult obstructive sleep apnea patients with narrow maxilla and nasal floor

Audrey Yoon ^a, Christian Guilleminault ^b, Soroush Zaghi ^c, Stanley Yung-Chuan Liu ^{d,*}

^a Section of Pediatric Dentistry and Orthodontics, Division of Growth and Development, UCLA School of Dentistry, Los Angeles, CA, USA

^b Division of Sleep Medicine, Department of Psychiatry and Behavioral Sciences, Stanford University School of Medicine, Stanford, CA, USA

^c UCLA Health, Santa Monica, CA, 90404, USA

^d Division of Sleep Surgery, Dept. of Otolaryngology-Head & Neck Surgery, Stanford University School of Medicine, Stanford, CA, USA

ARTICLE INFO

Article history:

Received 31 December 2018

Received in revised form

2 June 2019

Accepted 5 June 2019

Available online xxx

Keywords:

Distraction Osteogenesis Maxillary Expansion (DOME)

High arch palate

Mini-implant assisted rapid palatal expansion

Adult maxillary expansion

Obstructive sleep apnea

Narrow nasal floor

Skeletal expansion

Mini-screw assisted rapid palatal expansion

Snoring

Maxillary hypoplasia

Nasal obstruction

ABSTRACT

Objectives: This study correlates objective and subjective measurements associated with obstructive sleep apnea (OSA) to define the efficacy of Distraction Osteogenesis Maxillary Expansion (DOME) to treat adult OSA patients with narrow maxilla and nasal floor.

Methods: This is a retrospective study reviewing cases from September 2014 through April 2018 with 75 eligible subjects. Inclusion criteria required OSA confirmed by attended polysomnography (PSG). Pre- and Post-operative clinical data were measured at the Stanford Sleep Medicine and Stanford Sleep Surgery Clinics. DOME is a two-step process starting with insertion of custom-fabricated maxillary expanders anchored to the hard palate by mini-implants followed by minimally invasive osteotomies. After maxillary expansion was complete, orthodontic treatment to restore normal occlusion was initiated. Perioperative Apnea-Hypopnea Index (AHI), Epworth Sleepiness Scale (ESS), Nasal Obstruction Symptom Evaluation (NOSE), and Oxygen Desaturation Index (ODI) were measured for 43, 72, 72, and 34 subjects respectively. Statistical analysis was performed using paired T-test with significance set at p-value < 0.05. **Results:** The mean age of test subjects was 30.5 ± 8.5 years with a gender distribution of 57 males and 18 females. There was a significant reduction in pre and post-operative NOSE score (10.94 ± 5.51 to 3.28 ± 2.89 , $p < 0.0001$), mean ESS score (10.48 ± 5.4 to 6.69 ± 4.75 , $p < 0.0001$), and AHI (17.65 ± 19.30 to 8.17 ± 8.47 , $p < 0.0001$) with an increased percentage of REM sleep ($14.4 \pm 8.3\%$ to $22.7 \pm 6.6\%$, $p = 0.0014$). No significant adverse effects were identified.

Conclusions: DOME treatment reduced the severity of OSA, refractory nasal obstruction, daytime somnolence, and increased the percentage of REM sleep in this selected cohort of adults OSA patients with narrow maxilla and nasal floor.

© 2019 Elsevier B.V. All rights reserved.

1. Introduction

Maxillofacial and oropharyngeal anatomy are critical contributors to the pathophysiology of obstructive sleep apnea (OSA) [1]. Maxillary constriction with a high arch palate is associated with high nasal airway resistance. Coupled with decreased oral cavity volume, transverse deficiency of the maxilla is known as a contributor to the development of OSA [2].

In the pediatric population, rapid maxillary expansion (RME) corrects transverse deficiency of the hypoplastic maxilla by bony

expansion along the midpalate suture at the nasal floor. Overall, there is increased nasal cavity volume and decrease in nasal airflow resistance [3]. RME also allows the tongue to protrude forward and upward, thus expanding the posterior pharyngeal airway space during sleep [4]. A systematic review of scientific literature suggests that RME can be an effective treatment for pediatric OSA [5].

RME for younger children is achieved by placing a single oral appliance near the surface of the palate that is anchored to the posterior teeth bilaterally. Biologically, fusion of the midpalate suture occurs during the early teens and often coincides with the pubertal growth spurt [6]. Expansion of the maxilla after the sutures have fused often require surgical osteotomy to facilitate movement. Even with the surgical release of circum-maxillary and midpalate sutures, dental-borne expanders exert lateralizing forces

* Corresponding author. School of Medicine, Stanford University, 801 Welch Road, Stanford, CA, 94305, USA. Fax: +650 725 8502.

E-mail address: ycliu@stanford.edu (S.Y.-C. Liu).

on the anchored teeth, and expansion forces are exerted more on the supporting dental segments rather than the mid-palate or nasal floor. In 1964, a study by Krebs on orthopedic transverse modification demonstrated that expansion is 50% skeletal and 50% dental in younger children while the percentage dramatically skews to 35% skeletal and 65% dental in adolescents [7].

With the development of temporary skeletal attachments, bone mini-screws can be engaged directly into the maxilla to secure a RME appliance that applies mechanical forces to the bone, effectively bypassing teeth as anchor units. This creates new avenues of maxillary expansion and avoids undesirable tooth movement. This new category of mini-screw anchored maxillary expanders minimizes negative dentoalveolar effects, and achieves more nasal expansion as compared to conventional teeth-supported RME appliances [8,9].

Even with efforts to transfer lateral forces of RME expansion directly to the maxillary bone via mini-screws, the success of suture split and skeletal expansion without osteotomy is not predictable in the adult OSA population. To increase the predictability of maxillary skeletal expansion in adults, Distraction Osteogenesis Maxillary Expansion (DOME) protocol for adult OSA patients with narrow and high arch palate was developed at Stanford. DOME integrates minimally invasive osteotomy with mini-screw anchored RME device [10]. The technique for DOME was first published in 2017 [10]. The correlation between improvement in nasal breathing and increase of the internal nasal valve from DOME was later validated [11]. This paper describes sleep and nasal breathing outcomes after DOME of adult OSA patients with narrow maxilla and nasal floor.

2. Materials and methods

2.1. Subjects

This is a retrospective study of 75 subjects who underwent DOME after evaluation by Stanford Sleep Medicine (C.G.), Sleep Surgery (S.Y.C.L.), and Sleep Orthodontics (A.Y) from September 2014 to April 2018.

Inclusion criteria included: (1) adult patients with a diagnosis of OSA (based on attended polysomnography [PSG]), (2) intolerance to continuous positive airway pressure (CPAP) or other medical therapy, (3) narrow hard palatal roof, (4) Mallampati class 3 or 4, and (5) no palatine or lingual tonsillar hypertrophy.

Included subjects for this study generally fall into the following three categories:

- (1) OSA or Upper Airway Resistance Syndrome (UARS) patients who present with absolute skeletal transverse hypoplasia with a posterior dental crossbite,
- (2) Mild OSA or UARS patient, who does not have posterior crossbite, but present with persistent nasal obstruction with narrow nasal floor and high-arch palate (usually upper molars are superior convergent [12]),
- (3) Moderate to severe OSA patient preceding other sleep surgeries with skeletal maxillary hypoplasia and high-arch palate.

2.2. Distraction Osteogenesis Maxillary Expansion (DOME) protocol (Figs. 1 and 2)

2.2.1. Custom design and installation of expanders

Using 3-D cone-beam computed tomography (CBCT), custom-designed hybrid (bone-borne and tooth-borne) distractors were individually fabricated for each patient. The density and thickness of palatal bone gained from CBCT helped to identify the optimal

screw position and length. Mapping of suture location and fusion was also possible with the imaging. Mini-screws were placed with bicortical engagement of the palatal roof as close to the midpalate suture as possible given that sufficient bone thickness was present [13]. The orthodontist and surgeon work closely together on the treatment plan (Fig. 1).

2.2.2. Surgical technique (DOME)

DOME uses limited LeFort I osteotomy that does not require fracture of the pterygoid plates. Piezo-electric saw and osteotomes are used from an anterior maxillary approach to separate the left and right maxilla. When the suture opens, a small gap is seen between the maxillary central incisors. The expander screw is turned to validate the integrity of the screw threads with symmetric and easy separation of the maxilla bilaterally. Patients with mild to moderate OSA can be discharged on the day of surgery, while individuals presenting with severe OSA are monitored overnight. Blood loss is minimal. Septoplasty may be performed concurrently, especially in patients with severe posterior septal deviation at the vomer region.

2.2.3. Activation of expander and orthodontic treatment

The expander device is activated after 5–7 days post-surgery by activating an axial screw at a linear rate of 0.25 mm per day. On average, 8–12 mm of maxillary expansion is created. Once the expected expansion is complete, orthodontic treatment is initiated either using conventional fixed appliances or aligner therapy. Orthodontic treatment closes the spaces between dentition created by DOME and restores normal occlusion (Fig. 2).

2.2.4. Consolidation phase

In general, the consolidation phase is three months [14–16] for typical craniofacial distraction osteogenesis, but in order to allow maximal bone fill and minimize relapse, the expander is kept in place passively for an additional 6–8 months.

2.3. Polysomnography

Subjects followed an attended PSG process conducted and scored 3–8 months after DOME procedure according to the standards of the American Academy of Sleep Medicine. This included electroencephalography (EEG), electro-oculography (EOG), chin electromyography, and electrocardiography. Subjects had transcutaneous pulse oximetry, with respiratory effort recorded using inductance plethysmography. Apnea was defined as a decrease of baseline airflow (quantified by nasal cannula and mouth thermistor) by more than 90% for at least 10 s. Hypopnea was measured using a nasal pressure cannula and was defined as a partial obstructive event with decrease of airflow by 30% from baseline for at least 10 s associated with either a decrease in oxygen saturation by 3% or inducing an EEG arousal for at least 3 s.

2.4. Subjective measurements/Questionnaires

Epworth Sleepiness Scale (ESS) and Nasal Obstruction Symptom Evaluation (NOSE) questionnaires were completed before the DOME procedure and 3–6 months after completion of the DOME procedure.

2.5. Statistical analysis

Statistical analyses were performed using JMP Pro 14 (SAS Institute Inc., Cary, NC). Continuous variables are summarized as mean (M) \pm standard deviation (SD). Categorical variables are summarized as frequencies and percentages. Univariate analysis

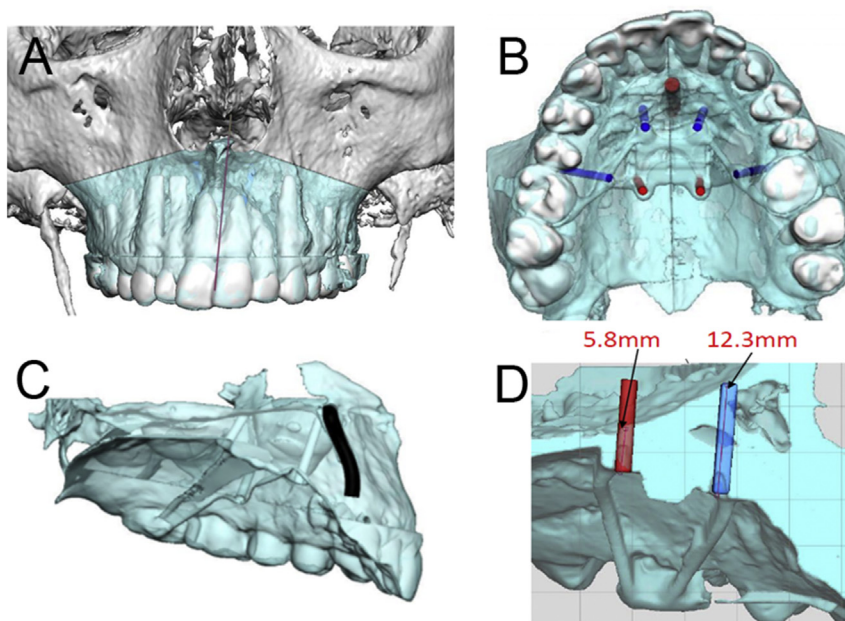


Fig. 1. DOME virtual planning. Using 3-D technology, custom-fabricate mini-implant assisted maxillary expander is designed and anatomies around surgical site is examined to achieve optimal results. A. Identify midpalatal suture location in relation to nasal floor and front teeth roots. B. Select ideal locations of mini-implants. C. Trace important anatomies including incisive canal. D. Measure the palatal bone thickness and select the ideal length of mini-implant on each location is identified.

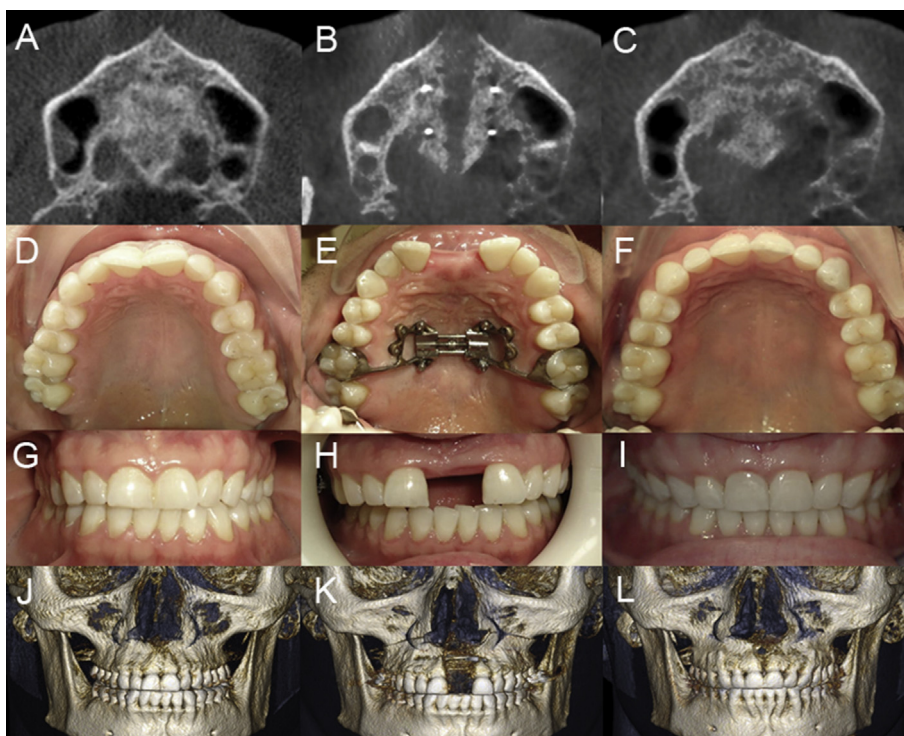


Fig. 2. Pre-DOME (left), post-DOME (middle) and post-orthodontic treatment (right). A. Pre-DOME transverse view of palate of CBCT. B. post-DOME transverse view of palate of CBCT. C. post-orthodontic treatment transverse view of palate of CBCT. D. Pre-DOME occlusal view. E. Post-DOME occlusal view. F. Post-orthodontic treatment occlusal view. G. Pre-DOME frontal view. H. Post-DOME frontal view. I. Post-orthodontic treatment occlusal view. J. Pre-DOME frontal view of CBCT 3D surface rendering. K. Post-DOME frontal view of CBCT. Maxillary bone with nasal floor was widen. L. Post-orthodontic treatment frontal view of CBCT. Diastema is all closed by orthodontic treatment while maintaining widened maxillary width and nasal floor.

with match-paired t-test (continuous variables) was performed to assess for mean differences in subjective and objective outcomes after the treatment intervention including ESS, NOSE, AHI, ODI, RDI, and other PSG variables. Standard error values are reported for

mean difference outcomes. A two-tailed p-value less than 0.05 was selected as the cut-off for statistical significance. Percent difference outcomes in post-op vs. pre-op results were reported for statistically significant outcome variables.

2.6. Ethics

This study was approved by the Institutional Review Board of Stanford University (Protocol 36385, IRB 6208).

3. Results

In total, 75 subjects underwent DOME with pre and post-operative data available for analysis, with 57 males (76%) and 18 females (24%). Baseline pre-operative age was 30.5 ± 8.5 years, height 177.7 ± 9.1 cm, weight 81.7 ± 20.5 kg, and BMI 26.0 ± 6.4 kg/m² (mean \pm SD). Exploratory univariate analysis was performed using 28 variables relating to demographic data, subjective questionnaires (ESS, NOSE), and PSG results (Table 1).

Perioperative AHI, ESS, NOSE, and ODI were obtained for 43, 72, 72, and 34 subjects. Analysis was performed using paired T-test with significance set at p-value of <0.05 .

The results showed a significant difference in pre and post-operative NOSE score (10.9 ± 5.5 to 3.3 ± 2.9 , $p < 0.0001$) and mean ESS score (10.5 ± 5.4 to 6.7 ± 4.8 , $p < 0.0001$). There was a significant reduction of AHI (17.7 ± 19.3 to 8.2 ± 8.5 , $p < 0.0001$). There is improved percentage of REM sleep ($14.4 \pm 8.3\%$ to $22.7 \pm 6.6\%$, $p = 0.0014$) (Table 2).

4. Discussion

The primary challenge in selection of surgery for the treatment of OSA is identification of anatomic phenotypes. DOME is proposed to widen a high-arch palate with associated nasal obstruction while improving symptoms of OSA. In this study, significant improvement with decreases in AHI, ESS and NOSE scores, as well

as increase in REM sleep, is shown for patients with narrow maxilla and nasal floor.

Prior to DOME, classic surgically-assisted palatal expansion techniques are often associated with aggressive surgery (pterygomaxillary separation) that can result in major complications including hemorrhage, mal-union, non-union, and high rates of relapse [17–19]. Comparatively, DOME is less invasive with minimal adverse side effect. It targets nasal floor expansion, particularly at the level of the internal nasal valve.

Of the 75 subjects enrolled, 18 subjects underwent subsequent planned maxillomandibular advancement (MMA) in the 9–12 months following DOME. For these combination cases, DOME resulted in healthier and wider maxillary bone surface for fixation. It obviates the need to do multi-segment maxillary surgery that is common for the correction of dentofacial deformity but has a poor track record in the treatment of OSA. Treatment with DOME prior to MMA surgery also allows more flexibility in the planning of jaw movement for optimal occlusion and facial balance.

No major complications (eg, non-union, mal-union, oro-nasal fistula, skeletal, nasal, sinus, or infections) have been reported with DOME. Minor asymmetric maxillary expansion occurred in a few cases, but within range of orthodontic correction. Resolution of V₂ paresthesia in the anterior maxilla ranged from 1 to 6 months. Maxillary central incisors occasionally showed signs of decreased perfusion. Loss of central incisor vitality requiring root canal treatment (but not loss of dentition) was reported in 5% of patients. Incisional dehiscence and periodontal attachment loss was observed in 2% of the patients. One patient reported palatal fistula which resolved without additional treatment. Another patient required minor bone grafting. These adverse effects from earlier cases have since decreased by delaying orthodontic therapy for a few weeks after full maxillary expansion.

Determining the amount of skeletal expansion necessary for improvement of OSA is not yet defined. Typical orthodontic measurements are based on arch width differences between maxillary and mandibular intermolar distance. With modern concept of skeletal expansion, measuring skeletal discrepancy rather than intermolar distance [12,20] is favorable to calculate the expansion amount. In the future, precision tools to measure airflow and pharyngeal critical pressure upon expansion would help planning for DOME more patient-specific. Design of the expander, location of mini-implant screws, and basal bone width and angulation all need to be considered for biomechanical control.

Table 1
Demographic data.

	Mean	Standard Deviation	Sample Size	p-value
Age (years)	30.5	8.5	75	N/A
Height (cm)	177.7	9.1	74	0.3425
Weight (kg)	81.7	20.5	72	0.9500
BMI (kg/m ²)	26.0	6.4	74	0.3984
Gender	76% Male (n = 57)	24% Female (n = 18)	75	N/A

Table 2
Questionnaires and sleep study outcomes.

	Pre-Op: Mean \pm SD	Post-Op: Mean \pm SD	Percent Difference	P-Value
ESS (24)	10.48 \pm 5.40	6.69 \pm 4.75	-36.2%	<0.0001
NOSE (20)	10.94 \pm 5.51	3.28 \pm 2.89	-70.0%	<0.0001
AHI	17.65 \pm 19.30	8.17 \pm 8.47	-53.8%	<0.0001
ODI	13.16 \pm 18.46	5.14 \pm 5.90	-60.9%	0.0051
RDI	17.67 \pm 19.86	8.85 \pm 8.92	-49.9%	<0.0001
AI	3.85 \pm 11.91	0.80 \pm 1.86	NS	0.1310
LOS	88.93 \pm 7.02	91.36 \pm 4.18	2.7%	0.0070
Total Sleep Period	450.18 \pm 97.85	471.96 \pm 72.47	NS	0.4009
Total Sleep Time	388.80 \pm 119.30	427.20 \pm 75.47	NS	0.1721
Sleep Onset Latency	20.93 \pm 11.96	17.86 \pm 14.07	NS	0.5656
Rem Latency	131.55 \pm 87.24	101.56 \pm 73.44	NS	0.2059
Sleep Efficiency %	82.93 \pm 13.09	83.69 \pm 11.35	NS	0.8037
NREM1%	13.47 \pm 10.08	9.39 \pm 6.63	NS	0.1940
NREM2%	56.13 \pm 14.97	54.89 \pm 13.33	NS	0.8220
Slow wave sleep %	12.36 \pm 9.39	11.48 \pm 10.80	NS	0.8493
REM Sleep %	16.12 \pm 7.82	23.31 \pm 7.23	44.6%	0.0140
Wake after sleep onset %	8.73 \pm 13.88	16.65 \pm 18.43	NS	0.2399

5. Conclusion

In this article, we present a larger pool of patients with OSA and narrow maxilla who underwent DOME. DOME significantly alleviates nasal obstruction, decreases AHI, and improves amount of REM sleep. However, DOME is a targeted anatomic intervention for adults with OSA presenting with narrow maxilla and nasal floor.

Financial support

No funding was received for this study.

Acknowledgement

We are thankful to our Stanford colleagues, Drs. Carlos Torre, Yu-Feng Chen, Chris Gouveia, Sasikarn Poomkonsarn, and Tyler Okland who helped us collect and analyze patient's data. We also thank Mr. Javier De Luna and Universal Orthodontic Lab for helping us develop customized maxillary expander.

Conflict of interest

The Authors declare that they have no conflict of interest.

The ICMJE Uniform Disclosure Form for Potential Conflicts of Interest associated with this article can be viewed by clicking on the following link: <https://doi.org/10.1016/j.sleep.2019.06.002>.

References

- [1] Cistulli PA. Craniofacial abnormalities in obstructive sleep apnoea: implications for treatment. *Respirology* 1996;1:167–74.
- [2] Cistulli PA, Richards GN, Palmisano RG, et al. Influence of maxillary constriction on nasal resistance and sleep apnea severity in patients with Marfan's syndrome. *Chest* 1996;110:1184–8.
- [3] Zambon CE, Cecchetti MM, Utumi ER, et al. Orthodontic measurements and nasal respiratory function after surgically assisted rapid maxillary expansion: an acoustic rhinometry and rhinomanometry study. *Int J Oral Maxillofac Surg* 2012;41:1120–6.
- [4] Iwasaki T, Saitoh I, Takemoto Y, et al. Tongue posture improvement and pharyngeal airway enlargement as secondary effects of rapid maxillary expansion: a cone-beam computed tomography study. *Am J Orthod Dentofac Orthop – Offic Publ Am Assoc Orthod Const Soc Am Board Orthod* 2013;143:235–45.
- [5] Machado-Junior AJ, Zancanella E, Crespo AN. Rapid maxillary expansion and obstructive sleep apnea: a review and meta-analysis. *Med Oral Patol Oral Cir Bucal* 2016;21:e465–9.
- [6] Persson M, Thilander B. Palatal suture closure in man from 15 to 35 years of age. *Am J Orthod* 1977;72:42–52.
- [7] Krebs A. Midpalatal suture expansion studies by the implant method over a seven-year period. *Rep Congr Eur Orthod Soc* 1964;40:131–42.
- [8] Mosleh MI, Kaddah MA, Abd ElSayed FA, et al. Comparison of transverse changes during maxillary expansion with 4-point bone-borne and tooth-borne maxillary expanders. *Am J Orthod Dentofac Orthop – Offic Publ Am Assoc Orthod Const Soc Am Board Orthod* 2015;148:599–607.
- [9] Deeb W, Hansen L, Hotan T, et al. Changes in nasal volume after surgically assisted bone-borne rapid maxillary expansion. *Am J Orthod Dentofac Orthop – Offic Publ Am Assoc Orthod Const Soc Am Board Orthod* 2010;137:782–9.
- [10] Liu SY, Guilleminault C, Huon LK, et al. Distraction osteogenesis maxillary expansion (DOME) for adult obstructive sleep apnea patients with high arched palate. *Otolaryngol Head Neck Surg – Offic J Am Acad Otolaryngol Head Neck Surg* 2017;157:345–8.
- [11] Abdelwahab M, Yoon A, Okland T, et al. Impact of distraction osteogenesis maxillary expansion on the internal nasal valve in obstructive sleep apnea. *Otolaryngol Head Neck Surg – Offic J Am Acad Otolaryngol Head Neck Surg* 2019. 194599819842808 [epub ahead of print].
- [12] Miner RM, Al Qabandi S, Rigali PH, et al. Cone-beam computed tomography transverse analysis. Part I: normative data. *Am J Orthod Dentofac Orthop – Offic Publ Am Assoc Orthod Const Soc Am Board Orthod* 2012;142:300–7.
- [13] Lee RJ, Moon W, Hong C. Effects of monocortical and bicortical mini-implant anchorage on bone-borne palatal expansion using finite element analysis. *Am J Orthod Dentofac Orthop – Offic Publ Am Assoc Orthod Const Soc Am Board Orthod* 2017;151:887–97.
- [14] Yu JC, Fearon J, Havlik RJ, et al. Distraction osteogenesis of the craniofacial skeleton. *Plast Reconstr Surg* 2004;114:1E–20E.
- [15] Swennen G, Schliephake H, Dempf R, et al. Craniofacial distraction osteogenesis: a review of the literature: Part 1: clinical studies. *Int J Oral Maxillofac Surg* 2001;30:89–103.
- [16] Gunbay T, Akay MC, Gunbay S, et al. Transpalatal distraction using bone-borne distractor: clinical observations and dental and skeletal changes. *J Oral Maxillofac Surg – Offic J Am Assoc Oral Maxillofac Surg* 2008;66:2503–14.
- [17] Dergin G, Aktop S, Varol A, et al. Complications related to surgically assisted rapid palatal expansion. *Oral Surg Oral Med Oral Pathol Oral Radiol* 2015;119:601–7.
- [18] Williams BJ, Currimbhoy S, Silva A, et al. Complications following surgically assisted rapid palatal expansion: a retrospective cohort study. *J Oral Maxillofac Surg – Offic J Am Assoc Oral Maxillofac Surg* 2012;70:2394–402.
- [19] Cakarer S, Keskin B, Isler SC, et al. Complications associated with surgically assisted rapid palatal expansion without pterygomaxillary separation. *J Stomatol Oral Maxillofac Surg* 2017;118:279–82.
- [20] Miner RM, Al Qabandi S, Rigali PH, et al. Cone-beam computed tomography transverse analyses. Part 2: measures of performance. *Am J Orthod Dentofac Orthop – Offic Publ Am Assoc Orthod Const Soc Am Board Orthod* 2015;148:253–63.